

# Facts and Fallacies of Radiation Risk in Dental Radiology

Professor Michael M. Bornstein

Dr. Andy Wai Kan Yeung

Dr. Carla Montalvao

Nicolas Colsoul

Professor Quentin A. Parker

Professor Reinhilde Jacobs



**Faculty of Dentistry**

The University of Hong Kong

香港大學牙醫學院





# **Facts and Fallacies of Radiation Risk in Dental Radiology**

**Professor Michael M. Bornstein<sup>1</sup>**

**Dr. Andy Wai Kan Yeung<sup>1</sup>**

**Dr. Carla Montalvao<sup>1</sup>**

**Nicolas Colsool<sup>1</sup>**

**Professor Quentin A. Parker<sup>2</sup>**

**Professor Reinhilde Jacobs<sup>3</sup>**

<sup>1</sup> Applied Oral Sciences, Faculty of Dentistry, The University of Hong Kong  
Prince Philip Dental Hospital, Sai Ying Pun, Hong Kong SAR, China

<sup>2</sup> Faculty of Science / Department of Physics and Laboratory for Space Research  
The University of Hong Kong, Cyberport 4, Hong Kong SAR, China

<sup>3</sup> OMFS IMPATH Research Group, Department of Imaging and Pathology  
Faculty of Medicine, University of Leuven, Leuven, Belgium and  
Department of Oral and Maxillofacial Surgery, University Hospitals Leuven, Leuven  
Belgium and Visiting Professor, Department Dental Medicine, Karolinska Institute  
Stockholm, Sweden



## Faculty of Dentistry

The University of Hong Kong

**Faculty of Dentistry, The University of Hong Kong**  
The Prince Philip Dental Hospital, 34 Hospital Road, Hong Kong  
<http://facdent.hku.hk>

Printed in Hong Kong

ISBN 978-988-79680-0-9

© 2019 Faculty of Dentistry, The University of Hong Kong

# Contents

<b>1</b>	<b>What is radiology?</b>	<b>4</b>
	Intra-oral radiographs (X-rays taken inside the mouth)	4
	Extra-oral radiographs (X-rays taken outside the body/mouth)	5
<b>2</b>	<b>What is radiation?</b>	<b>8</b>
	Radiation dose	9
	Radiation in dentistry	10
<b>3</b>	<b>Radiation dose protection in Dentistry</b>	<b>12</b>
	Children and radiation	12
	Pregnancy and radiation	14
	Elderly and radiation	14
	Patient protection measures	15
	Safety and quality control	16
<b>4</b>	<b>FAQs</b>	<b>18</b>
	Are dental X-rays really necessary?	18
	How often are dental X-rays recommended for adults and children?	18
	If I refuse to take X-rays, can I still be treated without them?	18
	Instead of taking X-rays now, can you use the X-rays from my previous dentist?	18
	How can I protect myself from radiation during X-ray taking?	19
	How safe are dental X-rays during pregnancy?	19
	Can radiation affect my child during breastfeeding?	19
	Why do I stay alone in the room when X-rays are recorded?	19
	Who owns my dental radiograph?	19
	Why does my dentist need to retake an image?	20
	How safe are dental X-rays?	20
<b>5</b>	<b>Acknowledgments</b>	<b>21</b>
<b>6</b>	<b>References</b>	<b>22</b>
	Publications	22
	Books and brochures	22
	Online resources	23

## • What is a radiology?

Radiology using X-rays is a key medical science. X-rays are high energy photons of electromagnetic energy. In medicine and dentistry it is common to use the word “X-rays” for images that are created when X-rays pass through tissue/bone and cause an exposure in a medium such as a photographic plate. Practical applications of radiology use various forms of imaging technologies for diagnostic purposes and for the treatment of diseases. Taking dental X-rays (dental radiology) is a sub-discipline of dental medicine. It includes the recording and interpretation of radiographic images (created using x-rays) used both for understanding what the problem is (diagnosis) and for the later planning of the treatment of any conditions, disorders or diseases of the mouth, jaws, and face that may be revealed. Experts within this field are known as specialists in Dental and MaxilloFacial Radiology (DMFR) or Oral and MaxilloFacial Radiology (OMFR).

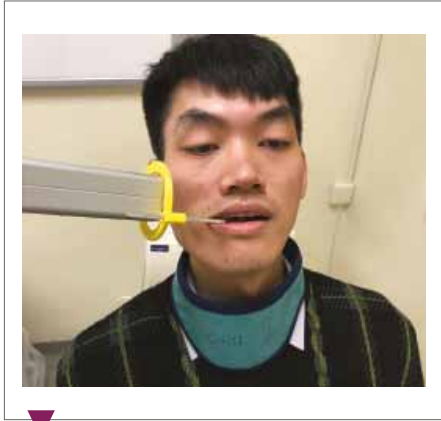There are different types of X-rays (radiographs) used in dentistry. These may be taken from outside the head/mouth area or from inside the mouth itself. The most common dental imaging techniques are the ones from inside the mouth, the bitewings and periapical X-rays (for details, please read below).

### **Intra-oral radiographs (X-rays taken inside the mouth)**

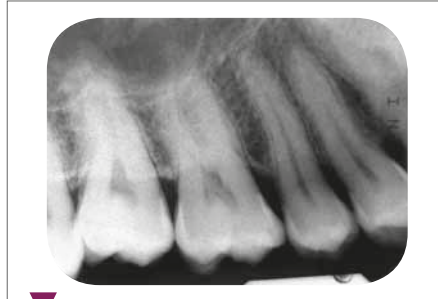The X-ray film is placed inside the mouth and can detect pathology. These modalities include:

- **Small area X-rays (also known as periapicals)** – these capture local images of teeth roots and surrounding bone. They can detect “invisible” problems under the gums or within bone such as gum disease. A small X-ray film is placed in the mouth and is exposed to a locally focused X-ray beam from a special machine. It has a restricted view being able to capture only two or three adjacent teeth at a time (see **Figures 1 and 2**);
- **“Bitewing”** – used primarily to identify hidden cavities between back teeth (i.e. the crumbling of teeth or bone in the spaces between teeth – so called “interproximal caries”) or under existing restorations (i.e. recurrence of caries). Teeth on the same side on both upper and lower jaws can be captured simultaneously on one image (**Figure 3**);
- **“Occlusal radiographs”** – these are useful to monitor and assess the front teeth in either the upper or lower jaw. This X-ray is more suited to visualize either the palate or floor of the mouth and respective bony anatomy (**Figure 4**).

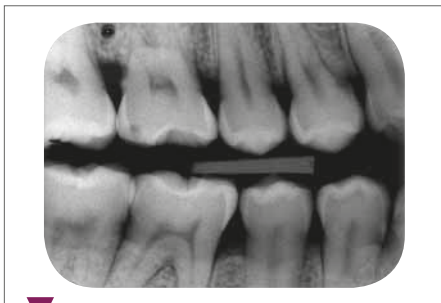
After taking the X-ray, two techniques can be used to show the image. The classic “analogue” technique is achieved in a darkroom by developing the exposed X-ray film or by using an automatic X-ray film processor. This technique is now largely replaced by modern “digital” technologies where images are created by a computer and digital X-ray sensors. Digital images require less X-ray radiation and can be easily adjusted on a screen to help in the diagnostic process. In addition, digital images can be easily stored, printed or electronically shared with other dental professionals.



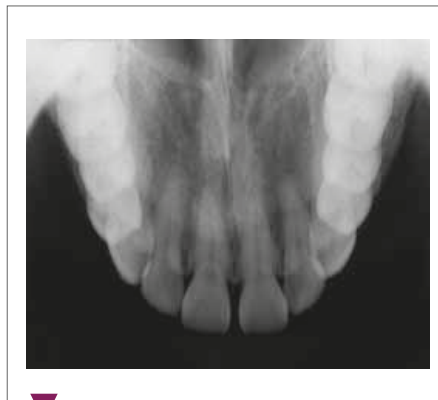
**Figure 1.** Image of an individual with an X-ray film that is held inside the mouth up against the area of interest with the X-ray imaging device held up against the cheek (this is generally called an intra-oral radiograph).



**Figure 2.** An example of a radiograph in the right upper jaw (premolars and molars visible).



**Figure 3.** An example of a bitewing on the right side revealing aspects of lower and upper premolars and molars.



**Figure 4.** An example of an X-ray of the upper jaw, exhibiting clearly the bone structures forming the roof of mouth (known as the palate), as well as the central and lateral incisors. Canines, pre-molars and molars are only partially visible or overlapping in the image.

### Extra-oral radiographs (X-rays taken outside the body / mouth)

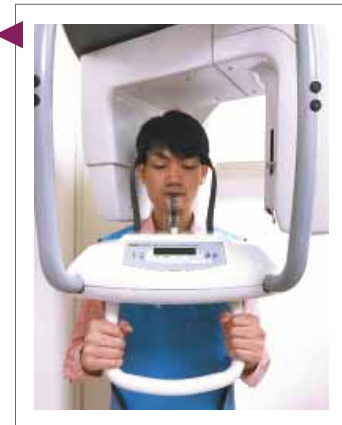The X-ray film or sensor is placed outside the mouth and aims to identify dental or skeletal anomalies of the jaw and skull. Extra-oral imaging modalities include:

- **Panoramic radiograph** – allows detection of teeth pathology (i.e. missing or extra teeth, tooth impaction etc.) and bone (i.e. cysts, tumors) as well as relations between the jaws and teeth. It enables the clinician to capture both jaw bones and respective teeth including the temporomandibular joints in one 2-D (two-dimensional) film (**Figures 5 and 6**);

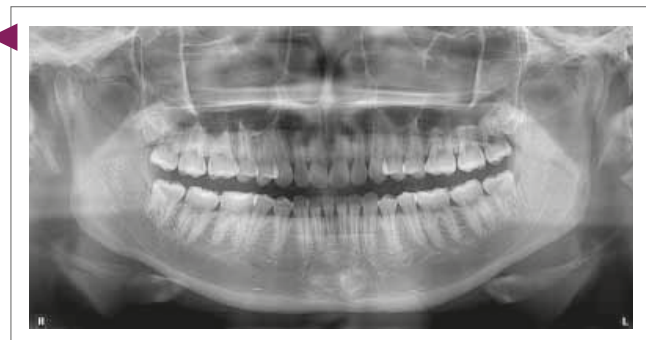

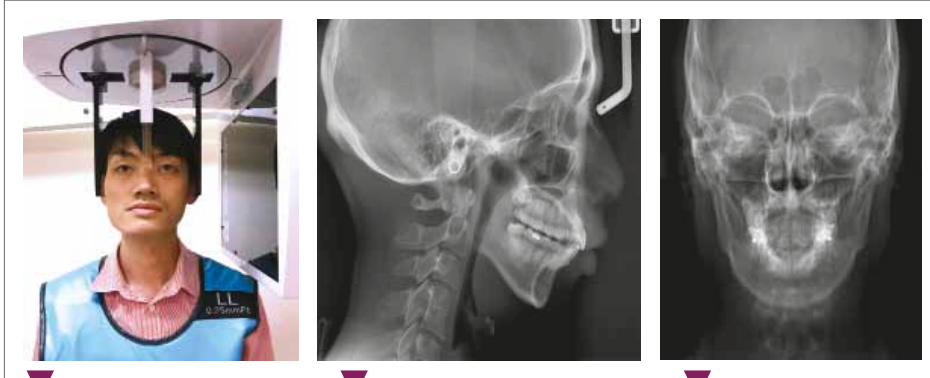
- **Cephalometric radiograph** – allows teeth analysis in relation to the jaw and profile of the individual, and shows the entire side (lateral aspect) of the head. Mainly orthodontists use this X-ray for treatment planning prior to teeth alignment (**Figures 7, 8 and 9**);
- **Cone Beam Computed Tomography (CBCT)** – more frequently used today than computed tomography (CT) by dentists to detect mouth and facial pathology (i.e. cysts, tumors). It is also used to evaluate tooth and bone morphology, and for treatment planning purposes (i.e. dental implant placement). CBCT is similar to conventional CT as both produce accurate and high quality images of mouth and facial structures in three dimensions. A CBCT machine rotates around the patient's head and captures all data in one single rotation, whereas a conventional CT collects “flat slices” by making several rotations around the patient's head. Consequently, CT imaging usually exposes the patient to a higher radiation dose compared to CBCT (**Figures 10, 11, 12 and 13**);
- **Computed tomography (CT)** – allows visualization of interior structures in 3-D (three dimensions) in contrast to traditional 2-D images, where the skull is displayed in one flat image with overlapping structures. 3-D imaging has the advantage of analyzing structures in more detail by scrolling through the slices in all three dimensions;
- **Magnetic Resonance Imaging (MRI)** – is a less frequent imaging method in dental medicine, which produces very clear images of the human body - specifically of soft tissues - without the use of X-rays, but with use of a large magnet, radio waves and a computer.

**Figure 5.** X-ray taking for extra-oral radiographs (here: a panoramic radiograph).



**Figure 6.** A representative panoramic radiograph depicting both jaws, the respective dentition, and the region of the temporomandibular joints on both sides.



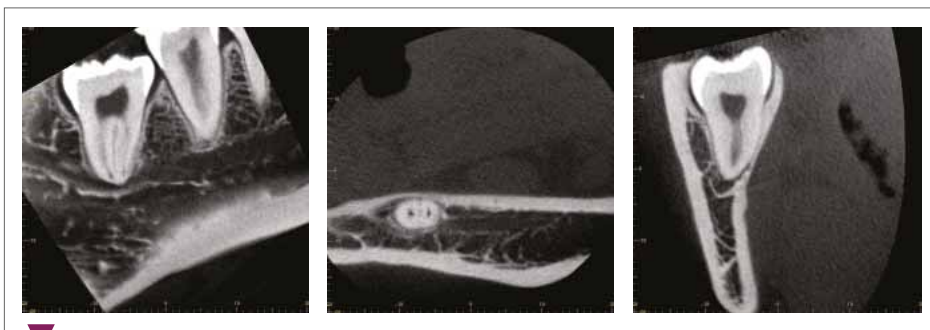


**Figure 7.** X-ray taking for extra-oral radiographs (here: a cephalometric radiograph).

**Figure 8.** An example of a cephalometric radiograph (lateral view) fully depicting the facial bone structures and parts of the cranium. Furthermore, it is also possible to observe the contour of the soft tissues (mouth, nose, etc.).

**Figure 9.** An example of a cephalometric radiograph (frontal view).

**Figure 10.** A representative example of a Cone Beam Computed Tomography (CBCT) device.



**Figure 11, 12, 13.** An example of a CBCT radiograph to evaluate the location of a lower right third molar and its relation towards the mandibular canal (nerve) of the lower jaw in three dimensions.

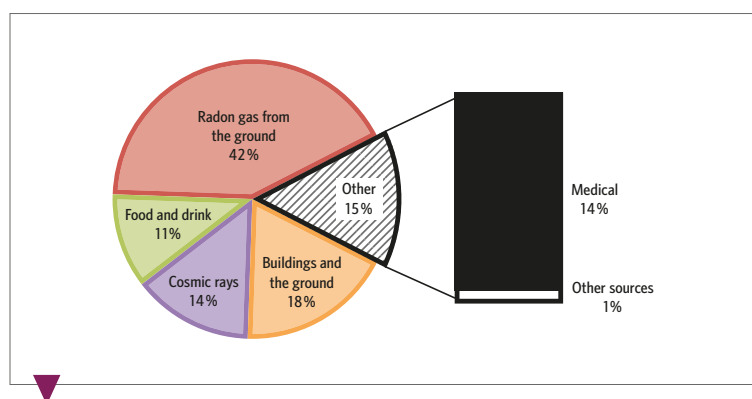


## • What is radiation?

Radiation can be described as photon energy (or particle energy) from a source that travels through space or another medium. The term **ionising radiation** is used if the photons or particles carry enough energy to liberate electrons from atoms or molecules, thereby ionising them. Such ionising radiation can be produced by X-ray machines that emit X-ray photons of sufficient energy to penetrate human bone and tissue.

**Radioactivity is a natural phenomenon and an integral part of our planet** and has always existed. Naturally, radioactive materials are present in the earth's crust, the floors and walls of our homes, but are also present in the food and drinks we consume. There are radioactive gases in the air we breathe as well, and our own body (i.e. muscles, bones, tissue) contains radioactive elements. In other words, humans have always been exposed to natural radiation arising from the spontaneous decay of radioactive elements within the earth such as uranium, caesium and thorium and even gases such as radon, and as well from outside of the earth (i.e. cosmic radiation; **Figure 14**). The physiological effects of these natural levels of radiation are extremely small but may play some role in the progress of genetic mutation and evolution.

We also receive exposure from **man-made radiation**, for instance the small quantities of radioactive materials released into the environment from coal and nuclear power plants. Additional sources of radiation include the medical use of X-rays for diagnostic purposes, radioactivity in nuclear medicine for cancer therapy, and when we travel by air at high altitude where radiation from space is less absorbed the higher up in the atmosphere we fly. Radiation used for therapeutic purposes can apply a dose to the organs under treatment much higher than our annual background radiation dose limit.



**Figure 14.** Pie chart illustrating the relative amount of annual radiation from exposure to natural sources and exposure to artificial sources. Medical radiation represents approximately 14% of the total annual dose for a typical human (data taken and adapted from the World Nuclear Association; the respective link is provided below in the "References" section).

## Radiation dose

This is a measure of how much energy is absorbed when somebody is exposed to X-rays or other ionising radiations such as high energy electrons or ions. Due to the deleterious effect to the human body the measure of this form of energy is extremely relevant. There are two main paths expressing radiation doses in dental procedures: the first one is the dose estimated at the patient's skin surface and the second one is the effective dose. It is easier to measure the dose estimated at the skin surface, and that is why it is often used in national surveys of X-ray equipment. Although the calculation of the effective dose is challenging, it is seen as more relevant due to a direct relation between this value and the radiation-associated risk to the individual.

The unit for the dose estimated at the patient's skin surface is called a **"Gray"** (Gy). In the context of dental radiology, dose levels generally are a small fraction of one gray (milli gray; mGy or even micro gray;  $\mu$ Gy- which is one millionth of a Gray). A risk measurement of the biological harm of radiation is the effective dose that tissues receive. This unit is indicated as a **"Sievert"** (Sv). Since one Sievert is a large quantity too, effective radiation doses normally are expressed in millisievert (mSv) or microsievert ( $\mu$ Sv), which are fractions of one-thousandth and one millionth of a Sievert. For example, one chest X-ray will give about 0.02 mSv of radiation dose (**Tables 1 and 2**).

Doses received by patients in a medical setup are generally justified because these exposures form a lesser risk to their wellbeing than does the threat of an undiagnosed or untreated disease. The risk-to-benefit ratio therefore is important to consider before executing diagnostic and therapeutic radiation.

**Table 1.** Effective radiation dose for existing dental X-rays devices and their equivalent to natural background radiation and a 7 hours flight. The radiation doses in this table are population averages only; the dose to an individual may be higher or lower than these values (table adapted based on material by the New South Wales (NSW) Agency for Clinical Innovation and the International Atomic Energy Agency, Australia, the respective link is provided below in the "References" section).

Radiology examination	Effective dose range (mSv)	Equivalent exposure to natural background radiation (2 mSv per year)	Equivalent of travel on a 7 hours flight (0.05 mSv)
MRI and Ultrasound examination	No radiation	N/A	< 1 time
X-ray tooth (dental x-ray)	0.004	< 1 day	< 1 time
X-rays jaw (panoramic)	0.014	< 3 days	< 1 time
X-ray chest (1 image)	0.02	< 4 days	< 1 time
X-ray skull	0.1	0 - 18 days	< 2 times
Cephalometric radiograph	0.002 - 0.003	< 1 day	< 1 time
CBCT (small "dento-alveolar" volumes)	0.034 - 0.652	6 days to 4.5 months	< 1 - 12 times
CBCT (large "cranio-facial" volumes)	0.03 - 1	7 days to 6.5 months	< 1 - 20 times
CT head / chest	1 to 5	6.5 months to 2.5 years	20 - 100 times
CT abdomen	>10	> 5 years	> 200 times

**Table 2.** The annual dose limit stipulated in the Radiation Ordinance for exposure of individuals resulting from the combination of all the relevant practices (table adapted from Radiation Health Series, Guidance Notes on Radiation Protection for Dental Radiology, Radiation Health Unit Department of Health of Hong Kong Government; the respective link is provided below in the “References” section).

Organs	Annual dose limit	
	Occupational	Public
Whole Body	20 mSv in any calendar year	1 mSv
Abdomen of woman with reproductive capacity	5 mSv in any consecutive 3 months interval	-----
Abdomen of a pregnant woman	1 mSv from declaration to delivery	-----
Lens of the eye	150 mSv	15 mSv
Skin, average over 1 cm <sup>2</sup>	500 mSv	50 mSv
Other individual organs	500 mSv	-----

## Radiation in dentistry

Dental X-rays have been responsible for a small amount of patient radiation, and their effects have been considered almost negligible. In order to facilitate the understanding of the impact of radiation, the amount of dental radiation dose is often compared to the amount of natural radiation a person gets from sitting on a plane or lying on the beach. In order to demonstrate the impact of dental radiation on the eventual risk of death, a comparative table has been provided below (**Table 3**).

**Table 3.** Average annual risk of death in Hong Kong from some common causes (table adapted from the Radiation Health Unit, Department of Health, Government of Hong Kong; the respective link is provided below in the “References” section).

Cause	Annual risk of death
Smoking 10 cigarettes a day	1 in 200
Malignant diseases	1 in 630
Occupational accidents	1 in 55 000
Traffic accidents	1 in 22 200
Occupational radiation exposure for local workers (average 0.15 mSv/year) <sup>5</sup>	1 in 170 333

Technology has changed substantially over the last few years. The change from classical film-based radiology —the standard for decades in the field—to digital imaging has had a great impact on the reduction of radiation dose. On the other hand, the advent of CBCT imaging or 3-D technology which has come with a higher radiation dose has more than offset reductions in dose to the public from switching from film to digital imaging.

To image a tooth, which is a calcified structure just like the other bones in our body, the amount of energy needed to penetrate is the same as for taking a bone tissue image. X-rays required for teeth are therefore very similar to X-rays for fingers, hands or feet. In reality, the processes of taking an X-ray of a tooth or a finger are almost the same. Following this principle of similarity, the amount of radiation dose required to penetrate the jaw to form an image on a panoramic X-ray has also a similar dose to the radiation needed to X-ray the elbow. Refer to Table 1 to observe the radiation dose among the several methods and types of diagnostic X-rays.

## • Radiation dose protection in Dentistry

Optimization of radiation protection was developed as a result of the increasing knowledge on radiation and its potential negative effect on people. The acronym **ALARA** (“As Low As Reasonably Achievable”) has been used since 1973, to designate the optimization of X-ray doses in order to minimize radiation dose exposure. More recently, ALARA has been replaced by the acronym **ALADA** (“As Low As Diagnostically Acceptable”).

To establish ALADA goals, clinicians try to apply doses that are appropriate for the clinical purpose. This will influence the selection of imaging devices and the settings used. Practical measures for ALARA and ALADA in dental practice comprise an awareness of the field of view (for all types of imaging, but especially for CBCT), exposure time, anatomical relation (radiosensitive organs), diagnostic justification and shielding.

Patient selection guidelines for dental radiographic examinations have been developed to help the dentist’s professional judgment on how to optimize the use of diagnostic imaging. Further, the concept of radiographic justification as well as the effective use of X-rays in a dental practice has been elaborated in detail by the **European and American Dental Association guidelines** which suggests:

- All radiographic examinations must be justified on an individual case basis by considering that the benefits to the patient should outweigh the potential harm. The expected benefit is that the radiographic examination can add new diagnostic information to facilitate the management of the patient;
- Unless a medical history taking and clinical examination have been performed, no radiograph should be made. It means that the concept of ‘routine radiography’ is unacceptable;
- When referring a patient for a radiographic examination, the dentist should provide enough clinical information to justify the examination.

### Children and radiation

Dental radiography is a useful diagnostic aid in oral examination of children. In many cases the radiographic findings add crucial information. However, the risks associated with radiography should not be neglected. Furthermore, it has been found that children are far more radiosensitive when compared with adults, they present approximately 3 to 5 times higher risk of mortality by cancer resultant from radiation. Therefore, increased attention should be paid to minimize the medical radiation exposures to children. All radiological procedures carried out on children must

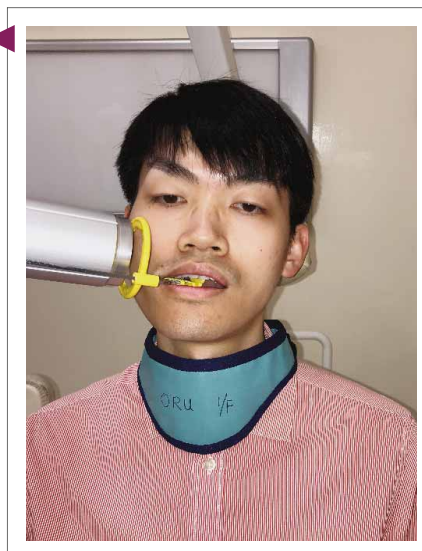adapt to special radiation protection measures, which aims at recognizing and implementing possible dose reduction strategies in order to eliminate unnecessary and therefore unjustified radiation exposure.

Since July 2007, the Alliance for Radiation Safety in Pediatric Imaging has created the Image Gently campaign to educate and raise the awareness regarding radiation safety. It is a worldwide coalition of healthcare organizations determined to provide safe, high quality pediatric imaging. The Society for Pediatric Radiology and over 33 other societies (such as the American Academy of Oral and Maxillofacial Radiology) formed this coalition, representing more than 500,000 worldwide health care professionals in radiology, dentistry, pediatrics, medical physics, and radiation safety. The Image Gently Campaign recommends to:

- Perform imaging only if there is clear medical or dental benefits to the child;
- Use the lowest amount of radiation for diagnostically acceptable imaging based on the body size of the child;
- Take images only on the indicated area and ideally use a thyroid collar (**Figure 15**)
- Avoid taking multiple and unnecessary images;
- Use alternative diagnostic techniques without radiation (e.g. ultrasound or MRI), if suitable.

The taking of a dental X-ray is not painful, but during the procedure, it is essential that the child remains still to limit the risks of the resultant image being fuzzy or of poor quality, thus requiring to be retaken. Occasionally, the parents will be asked to help in keeping their child steady while dental radiographs are taken.

**Figure 15.** Representation of lead-impregnated thyroid shield used during intraoral X-ray taking.

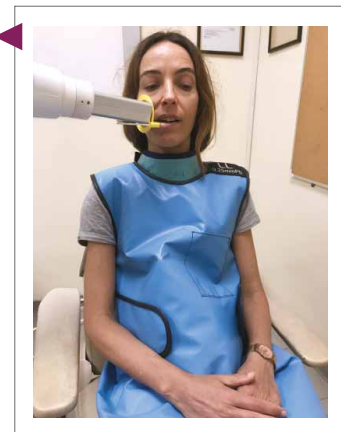




## Pregnancy and radiation

The ADA (American Dental Association) recommends the use of lead aprons and ideally a thyroid shielding for pregnant patients. In addition, the Hong Kong guidance on radiation protection specifies that the protective apron should have a protective equivalence of not less than 0.25 mm of lead (**Figure 16**). The American College of Obstetricians and Gynecologists Committee on Health Care for Underserved Women reaffirmed its opinion in 2015: “Patients often need reassurance that prevention, diagnosis, and treatment of oral conditions, including dental X-rays (with shielding of the abdomen and thyroid) ... is safe during pregnancy.” The patient however needs to be aware of a possible pregnancy and must inform the dentist. Due to the fetus vulnerability especially during the first trimester the dentist may decide to postpone non urgent treatments.

**Figure 16.** An example of lead apron used by a pregnant patient for dose protection during intra-oral radiography taking.



## Elderly and radiation

As adults age, radiation exposure becomes less of a concern (**Table 4**). The body tissues of the elderly are less sensitive to the effects of radiation. Nevertheless, standard protection measures are equally important.

**Table 4.** Risk in relation to age (table adapted from European Guidelines on Radiation Protection in Dental Radiology, European Commission; the respective link is provided below in the “References” section).

Age group (years)	Multiplication factor for risk
<10	x 3
10 - 20	x 2
20 - 30	x 1.5
30 - 50	x 0.5
50 - 80	x 0.3
80 +	Negligible risk

## Patient protection measures

Although, dental X-ray taking for diagnostic purposes is decided on individual needs, the radiation protection guidelines are common for the majority of the procedures. The department for Radiation Protection in Dental Radiology, Radiation Health Unit, Department of Health, Hong Kong Government has stipulated for the use of intra-oral films and extra-oral imaging the following guidelines:

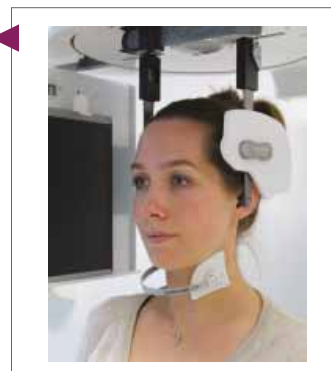- A woman who is, or who may be, pregnant should have the body covered by a protective apron with a protective equivalence of not less than 0.25 mm lead.
- Dental films should be held by the patient and by no one else; when the patient cannot hold it (i.e. a child or a handicapped person) then the person providing support should be given appropriate instructions and should wear protective clothing (e.g. a lead apron) if practicable.
- The X-ray should not be directed towards the genitals. When this direction cannot be avoided, the patients should be protected by a lead apron (at least 0.25 mm lead equivalent) large enough to cover the whole trunk (**Figure 17**); the use of lead aprons is recommended on the grounds of patient reassurance.
- During cephalometry the focal-spot to skin distance should never be less than 30 cm.

In addition, some cephalometric imaging devices might even incorporate thyroid and brain protection (**Figures 18 and 19**), which is of further reassurance to the patient.

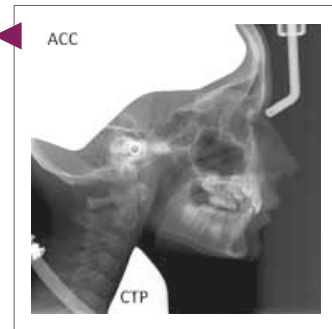
**Figure 17.** Representation of lead apron use during X-ray taking.



**Figure 18.** An example of thyroid and brain radiation protection during a cephalometric radiograph taking.



**Figure 19.** An example of cephalometric X-ray depicting the respective thyroid and brain radiation protection (white areas). The lack of image detail in these areas demonstrate the effectiveness of the protection mechanism by preventing X-ray penetration of these tissues.



### Safety and quality control

The radiation safety features of equipment should be maintained and checked according to the advice of the manufacturer or the supplier. At the Prince Philip Dental Hospital / Faculty of Dentistry of the University of Hong Kong these guidelines are followed by routine checks to detect if any deterioration in imaging quality or repeatability of radiographs occurs - and if the underlying cause is the deterioration in processing procedures or faulty X-ray equipment. Additionally, the Radiation Board will perform further routine and random inspections to assure patient and staff safety.

The Prince Philip Dental Hospital has also embraced preventive measures such as:

- Personal wearing of dosimeters for staff working in the “Oral Imaging” clinic.
- Use of barrier shielding for staff during exposures.
- Protective panel for the operator.
- Controlled areas for radiography:
  - a. controlled areas are exhibiting a warning notice stating that the area is controlled.
  - b. presence of radiation warning sign; may also include more detailed information, such as the reason why the area is controlled, e.g. “X-radiation”, and whether entry is permitted or not (**Figure 20**).
  - c. during radiography taking, staff are able to observe the condition of the patient through a lead glass window (**Figure 21**), or being protected by a control panel (**Figure 22**).

**Figure 20.** Example of a controlled area displaying a radiation warning sign and an active red light informing that entrance is currently not permitted.



**Figure 21.** Example of lead glass window enabling the observation of the patient during imaging. The lead glass absorbs the stray X-ray radiation.



**Figure 22.** Example of a protective panel for the operator.



### 1. Are dental X-rays really necessary?

Yes, as many diseases and conditions develop without any signs and symptoms. Tooth decay (caries) for instance, which is frequently located in between teeth, can be impossible to visualize during a clinical examination alone - especially in posterior teeth. Also cysts and tumors which are located inside the jaw bone can best be depicted properly using 2-D or 3-D X-ray images. X-rays are crucial for problem identification, diagnostic purposes, treatment planning, and to ensure a healthy condition of your mouth.

### 2. How often are dental X-rays recommended for adults and children?

Interval assessment of X-rays is made individually depending on your present oral health, age, risk for disease, and any signs or symptoms of oral disease. It is not uncommon for children to have X-rays more often because their teeth and jaws are still developing. Additionally, they are also more prone to suffer from tooth decay. Nevertheless, extensive or repeated X-ray examinations especially of children and pregnant women should not be undertaken without considerable forethought. Your dentist will review your medical and dental history, and examine your mouth first before deciding whether or not you need X-rays.

### 3. If I refuse to take X-rays, can I still be treated without them?

Yes, and this is part of the informed consent before initiating treatment. However, patients should know that X-rays are essential for a complete diagnosis and during treatment as not everything can be detected during the clinical examination alone. If X-rays are refused, important information may be missing.

### 4. Instead of taking X-rays now, can you use the X-rays from my previous dentist?

Yes, provided that they are recent and of acceptable diagnostic quality. The information of previous X-rays is actually very useful in the diagnostic process and disease management, as the evolution of a lesion can be carefully assessed. If x-rays are digitally available, ask your previous dentist for online access, and pass the respective images along to your current dentist. However, your dentist may still ask you to take new X-rays if he or she cannot be sure when or how the existing X-rays were taken.

## **5. How can I protect myself from radiation during X-ray taking?**

A lead apron (and thyroid collar as well) is part of the recommended radiation protection measures to protect reproductive, blood-forming, and thyroid tissues from scatter radiation. The lead acts as a shield and prevents the radiation from reaching these radiosensitive organs, which is especially important within the developing tissues of both children and pregnant woman.

## **6. How safe are dental X-rays during pregnancy?**

Future mothers should be aware that no single diagnostic dental X-ray has a radiation dose significant enough to cause adverse effects in a developing embryo or fetus. This is supported by various international organizations, who also emphasize the importance of appropriate shielding (i.e. lead apron) when pregnant. X-rays during emergencies are necessary for dental disease management. If not treated, the infection might spread through the bloodstream to the fetus, and (for example) periodontal disease may negatively affect pregnancy. X-rays during follow-up examinations however, can be postponed until after birth.

## **7. Can radiation affect my child during breastfeeding?**

At present, there is no evidence supporting special precautions with regard to children during breastfeeding. Dental X-rays are only present during the time that the image is being taken and leave no radiation or radioactivity in the body or in milk. Therefore, dental X-rays have no known effect on the milk in the breast at the time of imaging, nor on milk production.

## **8. Why do I stay alone in the room when X-rays are recorded?**

This is for the safety of the operator. When a patient is exposed to X-rays, they receive diagnostic benefits, while the dentist or X-ray operator does not. Also, while a patient is likely to be exposed with limited X-rays per year or during his lifespan, the dentist has to take thousands of X-rays. This could result in multiple more times of radiation compared to the patient. The dentist must use proper protection measures, and one of the most effective ways to limit their X-ray exposure is to maintain adequate distance and shielding. This is why they usually step out of the room during the X-ray exposure.

## **9. Who owns my dental radiograph?**

All your dental records, including the dental radiographs, are property of the dentist. Bound by professional secrecy, the dentist is obligated to store them securely and is responsible for any violations. A patient however has the privilege of reasonable access to his own dental records, and can request these from the dentist.



## **10. Why does my dentist need to retake an image?**

Several errors can occur during the X-ray image taking process such as motion artefacts, wrong focus distance, the desired information may not be visible or clear enough on the current radiograph, mechanical errors, etc. These complications might result in an X-ray that cannot be interpreted correctly, and thus is considered as not feasible for diagnosis. Therefore, this image has to be retaken.

## **11. How safe are dental X-rays?**

Compared to medical X-rays, dental x-rays generally have a lower radiation dose, and therefore should be safe when used with care and consideration by your dentist. Overall, the importance of making the right diagnosis and choosing the correct treatment makes X-rays far more beneficial than they are dangerous. Nevertheless, the benefits of such procedure is always weighed up before it's recommended.

# 5

## Acknowledgments

The authors thank Dr. Rainier Hogeveen, MSc, Department of Dental Radiology at ACTA Amsterdam, The Netherlands, for the provision of figures 18 and 19 (cephalometric radiology protection).

We thank also Prof. Cynthia Kar Yung Yiu, Paediatric Dentistry, Faculty of Dentistry, The University of Hong Kong, Hong Kong SAR, China, for sharing her expertise.

We further want to express our gratitude to Dr. Basak Harper, research assistant at Oral and Maxillofacial Radiology, Applied Oral Sciences, Faculty of Dentistry, The University of Hong Kong, Hong Kong SAR, China, for her help during the preparation of the manuscript.

### Publications

Abbott P. Are dental radiographs safe? *Aust Dent J* 2000; 45: 208-213.

American Dental Association Council on Scientific Affairs and U.S. Food and Drug Administration. Dental radiographic examinations: Recommendations for patient selection and limiting radiation exposure. *ADA* 2012: 16-17.

American Dental Association Council on Scientific Affairs. The use of dental radiographs. Update and recommendations. *J Am Dent Assoc* 2006; 137: 1304-1312.

Berkhout WE. The ALARA-principle. Backgrounds and enforcement in dental practices. *Ned Tijdschr Tandheelkd* 2015; 122: 263-270.

Evearitt A. The reality of dental radiation. *Journal of the Colorado Dental Association* 2016; 95: 28-30.

Giglio JA, Lanni SM, Laskin DM, Giglio NW. Oral health care for the pregnant patient. *J Can Dent Assoc* 2009; 75: 43-48.

ICRP International Commission on Radiological Protection. Radiological Protection in Medicine. ICRP Publication 105. *Ann ICRP* 37 (6).

Michalowicz BS, DiAngelis AJ, Novak MJ, Buchanan W, Papapanou PN, Mitchell DA, Curran AE, Lupo VR, Ferguson JE, Bofill J, Matseoane S, Deinard AS Jr, Rogers TB. Examining the safety of dental treatment in pregnant women. *J Am Dent Assoc* 2008; 139: 685-695.

Okano T, Sur J. Radiation dose and protection in dentistry. *Japanese Dental Science Review* 2010; 46: 112-121.

### Books & Brochures

#### European Guidelines on Radiation Protection in Dental Radiology:

[www.ec.europa.eu/energy/sites/ener/files/documents/136\\_0.pdf](http://www.ec.europa.eu/energy/sites/ener/files/documents/136_0.pdf)

Ianucci J, Howerton L. 2016, *Dental Radiography Principles and Techniques*. 5th Ed. Elsevier, Amsterdam.

#### International Commission on Radiological protection:

[www.icrp.org/docs/DRL\\_for\\_web.pdf](http://www.icrp.org/docs/DRL_for_web.pdf)

**NSW Agency for Clinical Innovation, Government of New South Wales, Australia:**  
[www.aci.health.nsw.gov.au/\\_\\_data/assets/pdf\\_file/0006/174552/MI-Clinician-Factsheet.pdf](http://www.aci.health.nsw.gov.au/__data/assets/pdf_file/0006/174552/MI-Clinician-Factsheet.pdf)

**Radiation Safety in Dental Practice – a study guide. California Dental Association:**  
[www.cda.org/Portals/0/pdfs/practice\\_support/radiation\\_safety\\_in\\_dental\\_practice.pdf](http://www.cda.org/Portals/0/pdfs/practice_support/radiation_safety_in_dental_practice.pdf)

**Radiation Health Series, Guidance notes on radiation protection for Dental Radiology, Radiation Health Unit, Department of Health of Hong Kong Government:**  
[www.info.gov.hk/dh-rhu/english/pdf/Pub4\\_english.pdf](http://www.info.gov.hk/dh-rhu/english/pdf/Pub4_english.pdf)

### **Online resources**

**American Dental Association:**  
[www.ada.org/en/~media/ADA/Science%20and%20Research/Files/topics\\_radiography\\_examinations\(1\)](http://www.ada.org/en/~media/ADA/Science%20and%20Research/Files/topics_radiography_examinations(1))

**Australian Nuclear Science and Technology Organization, Australian Government:**  
[www.ansto.gov.au/NuclearFacts/Whatisradiation/index.htm](http://www.ansto.gov.au/NuclearFacts/Whatisradiation/index.htm)

**International Atomic Energy Agency:**  
[www.iaea.org/resources/rpop/health-professionals/dentistry/pregnant-women](http://www.iaea.org/resources/rpop/health-professionals/dentistry/pregnant-women)

**Image Gently Alliance:**  
[www.imagegently.org/Roles-What-can-I-do/Parent/Dental](http://www.imagegently.org/Roles-What-can-I-do/Parent/Dental)

**National Health Service UK:**  
<https://www.nhs.uk/conditions/x-ray/>

**Radiation Health Unit, Department of Health, Government of Hong Kong Special Administrative Region:**  
[www.info.gov.hk/dh-rhu/english/html/understand\\_rad\\_english.htm](http://www.info.gov.hk/dh-rhu/english/html/understand_rad_english.htm)

**Radiation protection in dentistry. Recommended safety procedures for the use of dental x-ray equipment. Health Canada 1999, Government of Canada:**  
[www.canada.ca/en/health-canada/services/environmental-workplace-health/reports-publications/radiation/radiation-protection-dentistry-recommended-safety-procedures-use-dental-equipment-safety-code-30.html](http://www.canada.ca/en/health-canada/services/environmental-workplace-health/reports-publications/radiation/radiation-protection-dentistry-recommended-safety-procedures-use-dental-equipment-safety-code-30.html)

**World Nuclear Association:**  
[www.world-nuclear.org/nuclear-basics/what-is-radiation.aspx](http://www.world-nuclear.org/nuclear-basics/what-is-radiation.aspx)





## Faculty of Dentistry

The University of Hong Kong

The Prince Philip Dental Hospital  
34 Hospital Road  
Hong Kong SAR, China

<http://facdent.hku.hk>